

# Initial Experience of Corneal Collagen Cross Linking in Progressive Keratoconus

Munira Shakir, Faiza Rameez, Shakir Zafar, Muhammad Ahsan Sulaiman

*Pak J Ophthalmol 2018, Vol. 34, No. 2*

See end of article for authors affiliations

Correspondence to:  
Munira Shakir  
Liaquat National Hospital,  
Stadium Road, Karachi,  
Pakistan  
Email:  
dr\_munirasz@yahoo.com

**Purpose:** To assess the outcome of Corneal Collagen Cross-linking (CCXL) in patients with progressive Keratoconus in terms of satisfaction.

**Study Design:** Descriptive case series.

**Place and Duration of Study:** This study was conducted at Liaquat National Hospital, Karachi, Pakistan. It documents a process that is spread on one year.

**Material and Methods:** This prospective study is comprised of 34 patients who had bilateral Corneal Cross linking (CXL) treatment for progressive Keratoconus. Analysis was performed in terms of amount of corneal flattening (observed through topography), effect on vision (observed through Snellen's Chart) and satisfaction of patient (assessed by filling of proforma 6 months post-operatively).

**Results:** Findings of 31 cases were analyzed as 3 cases missed the follow-up. Mean age was  $23.2 \pm 5.5$  years. 61.3% of the cases were males while 38.7% were females with respective frequency of 19 and 12. Mean post-operative BCVA on Snellen's Chart improved on average by more than one line. Post-operative mean of change in steepest K reading was  $1.29 \pm 0.52D$ . 16.13% of the cases were happy after treatment, while 64.52% were satisfied. However, 19.35% of the cases were unhappy.

**Conclusion:** This study shows that CXL retards progression and generally brings satisfaction among the participants.

**Keywords:** Corneal Collagen Cross linking, Keratoconus, Corneal Topography.

**K**eratoconus is a condition characterized by corneal steepening typically inferior to central cornea with corneal thinning, induced myopia and both regular and irregular stigmatism. It is usually a bilateral condition and is non-inflammatory<sup>1</sup>.

The onset is around puberty with slow progression until third and fourth decades of life. Many treatment options are available including conservative options such as spectacles and rigid contact lenses. Surgical options for the treatment include: intra-corneal ring segments; Phakic Intra Ocular Lens (IOL); Refractive Lens Exchange (RLE); Anterior Lamellar Keratoplasty (ALK); and Penetrating Keratoplasty (PK)<sup>1-3</sup>.

A disturbed cross-linking within or among the collagen molecule has been observed in Keratoconus. By photo-oxidative collagen cross-linking with riboflavin and ultra violet light, additional covalent bindings between the collagen molecules is achieved which stabilizes the collagen scaffold<sup>1</sup>.

Eberhard Spoels and Theo Sieler developed Corneal Cross linking (CXL) procedure in late 1990s<sup>4</sup>. Wollensak et al<sup>5</sup> believed that collagen cross-linking was becoming a standard treatment for Keratoconus.

The aim of this case series is to evaluate the results of CXL in the patients with progressive Keratoconus and the index of patient satisfaction is being used as a main gauge for proving its effectiveness.

## MATERIAL AND METHODS

This study documents an ongoing case series, which was conducted in Liaquat National Hospital, Karachi, Pakistan. 34 cases of more than 10 years with central corneal ectasia and having commitment to follow up of six months were included in the study. Each patient was first time assessed at day one, then after a week, then monthly for 6 months and corneal topography was repeated at 3 and 6 months. Patients filled a proforma after topography. Exclusion criteria for this study was; any patient having corneal thickness less than  $400\mu\text{m}^6$ ; corneal scarring in the eye to be treated; loss to follow-up; prior history of corneal surgery.

This study was conducted after getting an informed written consent of all the participants. It was carried out under the supervision of an advisory committee.

Pre-operative complete ocular checkup was done including: Visual Acuity; Best Corrected Visual Acuity (BCVA) through Snellen's Chart; IOP through Goldman Applanation Tonometer; Corneal Topography by Pentacam; and Pachymetry (Ultrasonic and Pentacam). Further relevant information was collected, using a proforma, on follow ups. The CXL was done as a day-care procedure under sterilized environment. The inclusion criteria for this study, which is similar to O'bart et al<sup>7</sup> included; Age between 16 - 35, no prior history of ocular surgery, steepest K value between 48 D and 60 D, corneal thickness  $> 400 \mu\text{m}$ , patient must meet the diagnostic criteria for Keratoconus<sup>8</sup>, progression verified by corneal topography i.e.: Change of max. K by  $1\text{D}^9$ .

CBM VEGA X-linker - device that emits UV radiation at 365-370nm after proper calibration to direct  $5.4 \text{ J}/\text{cm}^2$  to the cornea - was used on all the participant of this study. Pre-operative antibiotics were given after the instillation of anesthetic drops. Seiler or epi-off technique was used. A lid speculum was applied. After removing the epithelium, drops of riboflavin 0.1% (Vitamin B2) were given at 1-5 minutes for 30 minutes or until it is visible in the anterior chamber. After riboflavin absorption, the participant was exposed to the UV light which was placed closer i.e. 1-5 cm from the corneal apex. A small digital video camera was included in the Ultra-Violet A (UVA) array in order to monitor the aiming beam. Following irradiation, cornea was rinsed with chilled saline, drops of antibiotic were applied and Bandage Contact Lens (BCL) was placed.

Post-operatively, topical antibiotics, topical steroids (4 times a day), artificial tears, painkiller and oral vitamin-C were given. BCL was removed after 3-4 days. This post-operative regimen was in line with Sherif et al<sup>10</sup>.

Data were analyzed using Minitab. Mean and standard deviation (SD) were used to define the variables. Frequency and percentage were used to define variables such as satisfaction index (ordinal variable) and gender. Descriptive statistics were developed and presented in the section of Results. P-value  $< 0.05$  was considered as significant for normality testing of data. Correlation of the two interval variables (Vision Improvement and Flattening) was further determined using Pearson Coefficient.

## RESULTS

34 cases were studied for this research; however, three cases were lost for follow-up. Analysis of the remaining 31 cases, who completed the follow-up, was carried out. All cases had progressive Keratoconus, and other ectasias were excluded from this study. For corneal stabilization, pre- and post-operative topographic readings were taken as criteria. In addition, BCVA was carried out through Snellen's Chart and was taken as another criterion. 61.3% of the cases were males while 38.7% were females with respective frequency of 19 and 12. Mean age was  $23.2 \pm 5.5$  years.

Mean post-operative BCVA on Snellen's Chart improved by more than one line. Specifically, the mean of change in vision improvement on Snellen's Chart was additional  $1.5 \pm 0.62$  lines. Post-operative mean of change in steepest K reading was  $1.29 \pm 0.52\text{D}$  as shown in Table 2. This shows improvement as the topographic findings showed lesser steepening post-operative. Normality test was applied on each variable's distribution, which were found to be non-normal ( $p < 0.1$ ); therefore, parametric statistical methods cannot be used and the scope was limited to descriptive statistics.

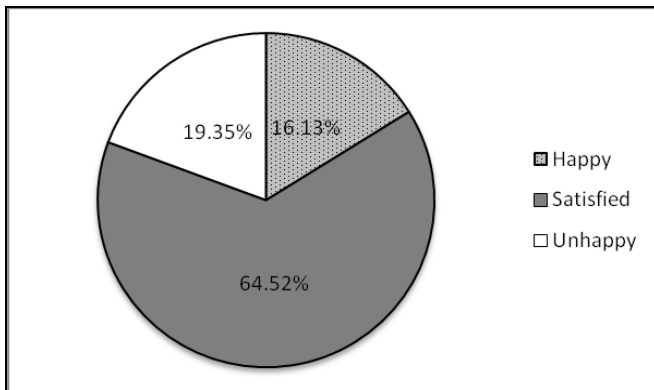
At 6 months post-operative, a proforma (placed as appendix) was filled for each case to gage the satisfaction. It had three options: happy, satisfied and unhappy; thus making it an ordinal variable. 16.13% of

**Table 2:** Post-operative description of Variables.

Variables	Mean*	SD	p-value for Normality**
Flattening	1.2903	0.5211	< 0.006
Vision Improvement	1.5145	0.6151	< 0.005

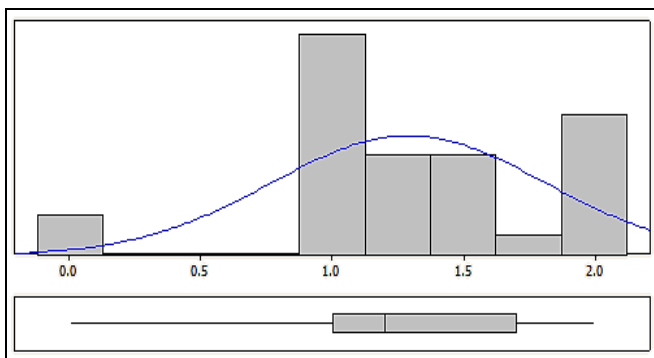
\*Mean: for flattening read' mean decrease in steepening', and; for vision improvement read' mean additional lines on Snellen's Chart'

\*\*Anderson-Darling Normality Test was used. As the p-values are lower than 0.1 significance level, the data do not follow the normal distribution



**Fig. 1:** Satisfaction Response (n = 31).

the cases were happy after treatment, while 64.52% were satisfied. However, 19.35% of the cases were unhappy, as shown in Figure-1. None of the cases developed any complications.



(a)

**Fig. 2(a):** Description of Flattening (Mean Line).

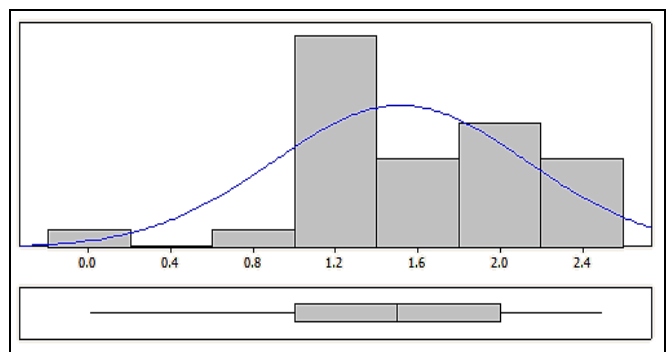
**DISCUSSION**

We have found a significant flattening in the steepest K value in all the patients similar to the results of Wollensak et al<sup>5</sup> in whose study the decrease of mean Keratometer value was by 2.01 D.

As compared to other therapeutic measures used for the treatment of Keratoconus such as: intra-corneal ring<sup>1,11</sup>; and epi-keratoplasty<sup>1</sup>; Hovkimyan et al<sup>12</sup>, showed that CXL can be regarded as a useful approach to reduce number of keratoplasties. Wollensak et al<sup>13</sup>, in their study showed that mechanical rigidity increases in porcine corneas, while they reported greater increase in human corneas. Figure-2 visually describes the mean flattening and mean vision improvements in our cases. Both distributions were found to be uni-modal and negatively skewed (as shown by the box plots as well). Furthermore, figure-3 presents the scatter plot developed between these two interval variables. It manifests a marginal positive correlation, which can be testified by the value of 0.779 of Pearson's Correlation Coefficient.

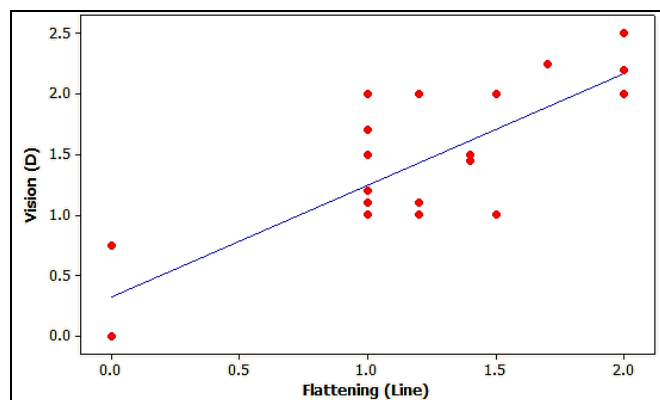
The findings of our study are in agreement with several earlier studies<sup>4,5,14-16</sup> that proved the significant improvement in visual acuity and maximum keratometry as well as retarding progression after CXL. However, our study further takes into account the satisfaction of the patients who went through the procedure. This was carried out using a designed proforma.

Wolensak et al.<sup>17</sup> in their study showed that riboflavin/UVA treatment is safe for endothelium only when the dose is below 0.65 J/cm<sup>2</sup> and cornea should not be less than 400 μm thick. Adverse



(b)

**Fig. 2(b):** Description of Vision Improvement (Mean D)



**Fig. 3:** Scatter plot of Vision (Mean D) versus Flattening (Mean Line).

outcomes have also been reported in different studies. Wolensak et al.<sup>18</sup> reported dose dependent keratocyte damage after riboflavin/UVA treatment, which can be expected in human corneas down to a depth of 300  $\mu\text{m}$  using a surface UVA dose of 5.4  $\text{J}/\text{cm}^2$ . Wolensak et al.<sup>19</sup>, indicated that combined riboflavin/UVA treatment leads to 10 fold lower threshold for keratocyte cytotoxicity at 0.5  $\text{mW}/\text{cm}^2$  compared to 5  $\text{mW}/\text{cm}^2$  after UVA irradiation alone.

## CONCLUSION

CXL has proved to be a safer and an effective procedure in the treatment of progressive Keratoconus and it usually results in satisfaction of the patient in terms of improvement of vision and retardation of the progression. Other studies have similar conclusions<sup>20</sup>.

### Author's Affiliation

Dr. Munira Shakir  
FCPS, FRCS Ophthalmology  
Associate Professor  
Liaquat National Hospital, Karachi.

Dr. Faiza Rameez  
MBBS, R5 Ophthalmology  
Liaquat National Hospital, Karachi.

Dr. Shakir Zafar  
FCPS Ophthalmology  
United Medical & Dental College, Karachi.

Muhammad Ahsan Sulaiman  
Final Year Medical student  
Liaquat National Hospital, Karachi.

### Role of Authors

Dr. Munira Shakir  
Surgeon who provided all the cases and who did all the surgeries. She is also a major contributor in writing this paper.

Dr. Faiza Rameez  
She assisted the surgeon in the surgeries. Majorly wrote the paper along with data collection and carrying out all descriptive statistics.

Dr. Shakir Zafar  
Surgeon whose experience was highly beneficial in analysis and conclusions of the findings.

Dr. Muhammad Ahsan Sulaiman  
Data collection and all data entry.

## REFERENCES

1. **Pinelli R, Leccisotti A.** Keratoconus Surgery and Cross-Linking; Jaypee Brothers Medical Publishers; 2009.
2. **Kanski JJ.** Clinical Ophthalmology: A Systematic Approach; Elsevier; 2007.
3. **Sandvik GF, Thorsrud A, Råen M, Østern AE, Sæthre M, Drolsum L.** Does corneal collagen cross-linking reduce the need for keratoplasties in patients with keratoconus? *Cornea*, 2015; 34 (9): 991-5.
4. **Khan MD, Ameen SS, Ishtiaq O, Niazi MK, Araeen MA, Naz MA, et al.** Preliminary Results of UV-A Riboflavin Cross linking in Progressive Cases of Keratoconus, in Pakistan Population. *Pak J Ophthalmol.* 2011; 27 (1): 21-6.
5. **Wollensak G, Spoerl E, Seiler T.** Riboflavin/Ultraviolet-A-induced Collagen Cross linking for the Treatment of Keratoconus. *Am J Ophthalmol.* 2003; 135: 620-7.
6. **Theuring A, Spoerl E, Pillunat L, Raiskup F.** Corneal collagen cross-linking with riboflavin and ultraviolet-A light in progressive keratoconus. Results after 10-year follow-up. *Ophthalmologie*, 2015; 112 (2): 140-7.
7. **O'brart DP, Kwong TQ, Patel P, McDonald RJ, O'brart NA.** Long-term follow-up of riboflavin/ultraviolet A (370 nm) corneal collagen cross-linking to halt the progression of keratoconus. *Br J Ophthalmol.* 2013; 97 (4): 433-7.
8. **Spoerl E, Wollensak G, Dittert D-D, Seiler T.** Thermomechanical behavior of collagen-cross-linked porcine cornea. *Ophthalmologica*, 2004; 218 (2): 136-40.
9. **Bikbova G, Bikbov M.** Transepithelial corneal collagen cross-linking by iontophoresis of riboflavin. *Acta Ophthalmol.* 2014; 92 (1).
10. **Sherif AM, Ammar M, Mostafa Y, Gamal Eldin S, Osman A.** One-year results of simultaneous topography-guided photorefractive keratectomy and corneal collagen cross-linking in keratoconus utilizing a modern ablation software. *J Ophthalmol.* 2015; 2015.

11. **Chan CC, Sharma M, Wachler BSB.** Effect of inferior-segment Intacs with and without C3-R on keratoconus. *J Cataract Refract Surg.* 2007; 33 (1): 75-80.
12. **Hovakimyan M, Guthoff RF, Stachs O.** Collagen Cross-Linking: Current Status and Future Directions *J Ophthalmol.* 2012; 1-12.
13. **Wollensak G, Spoerl E, Seiler T.** Stress-strain measurements of human and porcine corneas after riboflavin-ultraviolet-A-induced cross-linking. *J Cataract Refract Surg.* 2003; 29: 1780-5.
14. **Toprak I, Yaylali V, Yildirim C.** Factors affecting outcomes of corneal collagen crosslinking treatment. *Eye,* 2014; 28: 41-6.
15. **Kymionis GD, Grentzelos MA, Liakopoulos DA, Paraskevopoulos TA, Klados NE, Tsoulnaras KI, et al.** Long-term follow-up of corneal collagen cross-linking for keratoconus—the Cretan study. *Cornea,* 2014; 33 (10): 1071-9.
16. **Sykakis E, Karim R, Evans JR, Bunce C, Amisshah-Arthur KN, Patwary S, et al.** Corneal collagen cross-linking for treating keratoconus. *Cochrane Libr.* 2015.
17. **Wollensak G, Spoerl E, Wilsch M, Seiler T.** Endothelial cell damage after riboflavin-ultraviolet-A treatment in rabbit. *J Cataract Refract Surg.* 2003; 29: 1786-90.
18. **Wollensak G, Spoerl E, Wilsch M, Seiler T.** Keratocyte Apoptosis After Corneal Collagen Cross-linking Using Riboflavin/UVA Treatment. *Cornea,* 2004; 23 (1): 43-9.
19. **Wollensak G, Spoerl E, Reber F, Seiler T.** Keratocyte cytotoxicity of riboflavin/UVA-treatment in vitro. *Eye,* 2004: 1-5.
20. **Meiri Z, Keren S, Rosenblatt A, Sarig T, Shenhav L, Varssano D.** Efficacy of corneal collagen cross-linking for the treatment of keratoconus: a systematic review and meta-analysis. *Cornea,* 2016; 35 (3): 417-28.